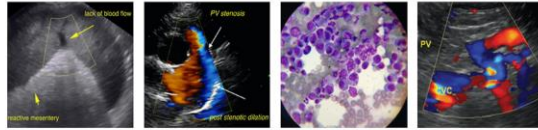


IMAGING PERFORMED BY

PAMobileVet.com 443-794-4700



EDUCATIONAL TELECONSULTATION SERVICES™

1-800-838-4268 info@sonopath.com SonoPath.com

PATIENT PRESENTING CLINICAL SIGNS

Rusty Parker
History: Heart 'murmur', lethargy, distended abdomen, renal disease, hypertension, hypertensive retinopathy
Medication: Amlodipine

SPECIES

Feline

ECHOCARDIOGRAPHIC FINDINGS

Multiple 2D, M-mode, and Doppler video loops and still images are submitted for review.

BREED

DSH

Left atrial size is normal. The mitral valve appears normal. Left ventricular wall thickness is normal. Left ventricular internal dimensions are normal. Left ventricular systolic function is normal. The aorta and aortic valve appear normal. Right atrial and right ventricular dimensions are normal. The tricuspid valve appears normal. The pulmonary artery and pulmonic valve appear normal. No heartworms are visualized. No pericardial effusion or cardiac masses are seen.

SEX

Male Neutered

AGE

15 years

LA/Ao - 1.38
IVSd - 4.8 mm
LVPWd - 4.7 mm
LVIDd - 13.6 mm
LVIDs - 7.2 mm
FS - 47%
RA - 8.5 mm
RVOT - 1.44 m/s

WEIGHT

11.9 lbs

ASSESSMENT/RECOMMENDATIONS

INTERPRETED BY

Normal echocardiogram

Keith Blass, DVM,
MS, DACVIM

This examination demonstrates no evidence of structural heart disease. While a definitive reason for Rusty's murmur was not identified, it's likely that his murmur is functional/innocent in nature, as no flow abnormalities that could result in the development of a pathologic murmur were appreciated in the image set.

IMAGING PERFORMED BY

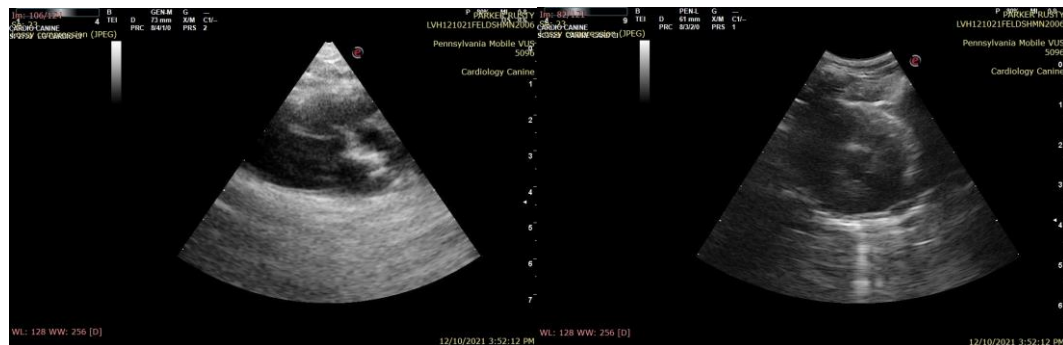Rebekah Jakum, CVT
ARDMS/RVT

No therapy is recommended based on this exam.

A recheck echocardiogram is recommended if the characteristics of Rusty's murmur change, or if other new physical exam and/or clinical abnormalities suggestive of structural heart disease develop.

HOSPITAL NAME

Littlestown VH



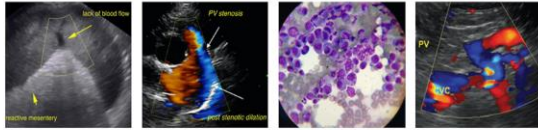
REFERRING VET

Dr. Wimer

DATE

12.10.2021

The information and recommendations provided are based on the images presented by the referring veterinarian.



PATIENT No evaluation can be communicated regarding pathology that was not visible in the image/video clips provided.

Rusty Parker

SPECIES

Feline

BREED

DSH

SEX

Male Neutered

AGE

15 years

WEIGHT

11.9 lbs

INTERPRETED BY

Keith Blass, DVM,
MS, DACVIM

**IMAGING
PERFORMED BY**

Rebekah Jakum, CVT
ARDMS/RVT

HOSPITAL NAME

Littlestown VH

REFERRING VET

Dr. Wimer

DATE

12.10.2021

Thank you for this referral. If the clinical or image interpretation does not parallel your findings or if I can be of any further assistance please contact me.

Keith Blass, DVM, MS, DACVIM (Cardiology)

KeithBlass@gmail.com

631-804-5754